

Memory Aid Example (for Anatomy & Physiology course)

Memory Aid (with explanations - used for studying only!)

Priorities for treating an injured person: **ABC** (airway, breathing, circulation)

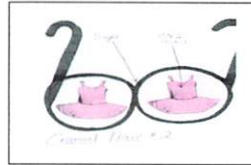
Treating a person in shock: **WART** (Warmth, ABCs, Rest and Reassurance, Treatment)

The Carpal bones of the hand: **Sally Likes To Play The Tiny Chrome Harmonica** (Scaphoid, Lunate, Triquetrium, Pisiform, Trapezium, Trapezoid, Capate, Hamate)

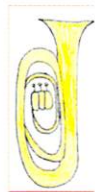Pain history checklist: **OLDER SAAB** (Onset, Location, Description, Exacerbating factors, Radiation, Severity, Associated symptoms, Alleviating factors, Before (ever experience this before))



TIRE represents the abdominal muscles: **T**ransversus, **I**nternal oblique, **R**ectus abdominus, **E**xternal oblique

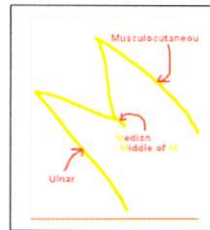


2nd cranial nerve is sight
(I SEE 2 tutus)



Fibula
thin like a
flute,
Tibia
thick like
a Tuba

The
median
nerve is
the middle
of a giant
capital M



Three B's Bend the elbow (muscles that flex elbow): **B**racialis, **B**iceps, **B**rachioradialis

Memory Aid (the one approved by professor and take in to exam)

ABC

WART

Sally Likes To Play The Tiny Chrome Harmonica

Three B's Bend the elbow

OLDER SAAB

